

Original Article-General Surgery

To study Complications and treatment of breast abscess of post-operative pain

¹ Chekka Ramanujam, ²Pydi Maheswara Rao, ³* K.V.S.S.Geethanand,

¹ Assistant Professor of General Surgery, Sardar Rajas Medical college and Hospital

² Associate Professor of General Surgery, NRI Institute of Medical Sciences

³ Associate Professor of General Surgery, Maharajahs Institute of Medical Sciences

***Corresponding Author:**

Dr. K.V.S.S.Geethanand,

Associate Professor of General Surgery,

Maharajahs Institute of Medical Sciences

Email id: drvrkk@gmail.com

Abstract:

The incision and drainage of acute abscesses. Today this remains a widely used conventional method even though it has a number of disadvantages such as repeated, painful dressing changes and delayed convalescence, leading to wasted time in the postoperative period. Present study intends to compare two methods- invasive method is conventional incision and drainage and minimally invasive procedure is percutaneous placement of suction drain in the treatment of breast abscess with reference to complications like post operative pain, duration of hospital stay, time required for complete healing. Post operative pain, Residual abscess, time for complete healing and hospital stay is better with closed drainage of breast abscess.

Key words:Breast abscesses,Hospital stay,postoperative pain.

Introduction:

A breast abscess is a localized collection of pus in the breast; usually occur in breastfeeding woman due to trauma and mastitis. Breast abscesses are most common in young lactating women. The incidence of abscesses in young women during their lactational period ranges from 0.4 to 11%. Mostly researchers reported Staphylococcus aureus is among the common cause for the infection. The human breast consists of parenchymal and stromal elements. The parenchyma forms a system of branching ducts eventually leading to secretory acini development and the stroma consists mainly of adipose tissue, providing the environment for development of the parenchyma⁽¹⁻³⁾. These building blocks of the breast are recognized as early as the embryonic stage of human development. The process of development of the ductal system and acini is termed branching morphogenesis and although it commences in the fetus, it halts in early childhood until puberty when hormonal stimulation triggers further differentiation⁽⁴⁾. An abscess is a collection of infected fluid within the breast tissue. The aim of treatment is to cure the abscess quickly and effectively, ensuring maximum benefit to the mother with minimal interruption of breastfeeding.

The benefits of breastfeeding are well known, and the World Health Organization recommends exclusive breastfeeding for the first six months of life and continuing breastfeeding to age two. However, many women stop breastfeeding due to lactational breast abscesses. A breast abscess is a localized accumulation of infected fluid in breast tissue. Abscesses are commonly treated with antibiotics, incision

and drainage (I&D) or ultrasound-guided needle aspiration, but there is no consensus on the optimal treatment.

Breast abscess is the result of underlying inflammation (mastitis) in the breast skin. Injury may happen either during the lactation process from the infant or in the non-lactation state of the patient as a cracking in the breast skin. This injury accelerates the entry of the causative bacteria which by its role form the abscess.² In neglected cases, there may be necrosis in the abscess location leads to fibrosis, scarring and nipple retraction. The conventional treatment of breast abscess has been surgical incision and drainage. Drainage of breast abscess has undergone a gradual change from invasive to minimally invasive procedure in keeping with the current philosophy of surgery. The standard surgical approach (invasive) of incision and drainage (I and D), breaking of loculi and insertion of a drain under general anesthesia or daily gauze packing has yielded to minimally invasive approach of percutaneous placement of suction drain and aspiration of the abscess with ultrasound guidance.

The present study intends to compare two methods- invasive method is conventional incision and drainage and minimally invasive procedure is percutaneous placement of suction drain in the treatment of breast abscess with reference to complications like post operative pain, duration of hospital stay, time required for complete healing.

Material and methods:

The patients attending outpatient department & admitted to Maharajahs Institute of Medical Sciences, Sardar Rajas Medical college and Hospital and , NRI Institute of Medical Sciences, India, with diagnosis of breast abscess will be taken for this study. Minimum of 60 cases will be taken up for study following inclusion and Exclusion criteria. By period sampling. The patients selected for this study are those who are with primary diagnosis of breast abscess. Based on detailed history, thorough clinical examination, the diagnosis of breast abscess will be made. These patients will be subjected to the required preoperative investigations. Patients will be alternately undergoing incision drainage and percutaneous placement of suction drain. Each case will be analysed with reference to post operative complications like post operative pain (based on visual analog scale), residual abscess, duration of hospital stay, time required for complete healing and appearance of scar and cost spent for treatment. Each patient will be followed up in the outpatient department at 1 week, 2 weeks, 3 and 4th weeks after discharge with regard to wound healing. A minimum of 60 cases with the following inclusion and exclusion criteria will be selected for the study and will be allocated alternatively to each of the comparative study groups.

Results:

Table.1: shown Post operative pain

Figure.1 shown pain and Post operative pain **Figure.2** shown Hospital stay and time of complete healing

Discussion:

The established principle of surgical management of abscess has been incision and free drainage. This modality of treatment has been challenged with the introduction of antibiotics. Ellis taught that the wall prevented access of blood to abscess cavity and that if this wall was curetted away the cavity could fill with antibiotic permitting safe primary closure. The primary suction closure technique is supported by many surgeons who showed its effectiveness in the treatment of breast abscess. Advantages of closure technique are faster healing rate, less hospital stay and early return to work, no greater recurrence than the conventional method, better scar formation and finally reduced cost of labor and material and may be recommended as an alternative treatment that is superior to the orthodox technique. In our study, we compared the outcome of conventional incision and drainage of acute abscess versus incision and drainage with primary closure of wound with negative suction drain in breast abscesses. Hence, we

performed a comparative study of the conventional method of incision and drainage with open drainage and primary closure. Open drainage with primary closure is effective alternative method of treatment to incision and drainage in properly selected patient and with timely support by sonologist. Conventional Incision and drainage of breast abscess leads to more pain, delayed healing and prolonged cessation of breast feeding.

All breast abscesses that were treated with incision and drainage healed. Studies did not report sufficiently on the number of follow-up visits, duration of continuation of breastfeeding, post-operative complications, duration of hospital stay and adverse events. However, it appeared that women were more satisfied when treated with needle aspiration.

One study compared different regimens of antibiotics versus no antibiotics in breastfeeding women who were treated with incision and drainage for breast abscesses. We did not find any difference between groups for the outcome resolution of breast abscesses and infections after the procedure.

All of the studies were poorly conducted and/or reported and did not address all of the outcomes that we were interested in. Studies with better design and reporting are needed to properly assess these outcomes.

In the present study post operative pain is measure according to visual analogue scale and analgesic requirement. In group I (closed drainage) has reduced post operative pain (80%) when compared to patient underwent open drainage 40% with significant in $P < 0.001$. When we are correlating this study with other studies, were found similar findings⁽⁵⁻⁸⁾. In post-operative period open incision and drainage had more pain give to due repeated dressings and closed drainage was void of it. Previous studies⁽⁹⁾ were found, the primary closure technique was superior to the conventional technique in terms of duration of healing, post operative pain, number of dressings required, length of hospitalization and post operative complications and quality of healing. In the study mean duration of hospital stay and time required for complete healing is of significance < 0.001 . Similar finding was observed in a study conducted by other study⁽¹⁰⁾ they found that hospitalization was reduced by 40-60% in closed drainage (group I).

There is insufficient evidence to determine whether needle aspiration is a more effective option to I&D for lactational breast abscesses, or whether an antibiotic should be routinely added to women undergoing I&D for lactational breast abscesses. We graded the evidence for the primary outcome of treatment failure as *low quality*, with downgrading based on including small studies with few events and unclear risk of bias.

Conclusion:

All patients complaint of swelling, pain and all and showed signs of inflammation. Closed drainage is effective alternative method of treatment to incision and drainage in properly selected patients. Conventional incision and drainage of breast abscess leads to more pain, delayed healing and prolonged cessation of breast feeding. Furthermore Post operative pain, Residual abscess, time for complete healing and hospital stay is better with closed drainage of breast abscess.

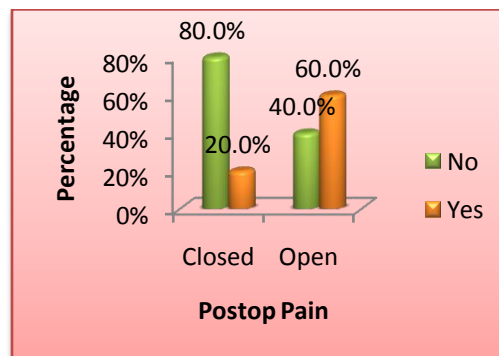
References:

1. Saleem S, Farooq T, Khan N, Shafiq M, Azeem M, Dab RH. Puerperal breast abscesses; percutaneous ultrasound guided drainage compared with conventional incision and drainage. Professional Medical Journal Dec 2008; 15(4): 431-436.

2. Tewari M, Shukla HS. An effective method of drainage of puerperal breast abscess by percutaneous placement of suction drain. Indian Journal of Surgery Dec 2006; 68(6): 330-333.
3. Karstrup S, Nolsoe C, Brabrand K, Nielsen KR. Ultrasonically guided percutaneous drainage of breast abscesses. Acta Radiology 1990; 31(2): 157-159.
4. Berna JD, Garcia-Medina V, Madrigal M, Guirao J, Llerena J. Percutaneous catheter drainage of breast abscess. European Journal of Radiology 1996; 21: 217-9.
5. Edino ST, Ihezue CH, Obekpa PO. Outcome of primary closure of incised acute soft-tissue abscesses. Niger Postgrad Med J 2001; 8: 32 -6.
6. Ajao OG, Ladipo JK, al-Saigh AA, Malatani T. Primary closure of breast abscess compared with conventional gauze packing and daily dressings. West Afr J Med. 1994 Jan-Mar/13(1):28-30.
7. Jones NA, Wilson DH. The treatment of acute abscesses by incision, Primary curettage and primary suture under antibiotic cover. B. J Surg 1976; 63(6): 499-501.
8. Kale A, Athavale V, Deshpande N, Nirhale d, Culcuttawala M, Bhatia M. Comparative study of conventional incision and drainage verses incision And drainage and primary closure of wound in acute abscesses. Med J D.Y. Patil Univ. 2014. Vol-7, 744-7.
9. Dubey V, Choudhary SK. Incision and drainage versus incision and drainage with primary closure and use of closed suction drain in acute abscesses. Wounds 2013; 25: 58-60.
10. Robinson G W, Karpf A B, Kratochwil K. Regulation of mammary gland development by tissue interaction. J Mammary Gland Biol Neoplasia. 1999;4(1):9–19. [PubMed] [Google Scholar]
11. Abraham N, Doudle M, Carson P. Open versus closed surgical treatment of abscesses: A controlled clinical trial. Aust N Z J Surg 1997;67:173-6.

Table.1: shown Post operative pain

Postop pain	Closed		Open		Total		Chi-square test	p-value
	N	Percentage	N	Percentage	N	Percentage		
No	24	80.0%	12	40.0%	36	60.0%	10.000	0.0010
Yes	6	20.0%	18	60.0%	24	40.0%		
Total	30	100.0%	30	100.0%	60	100%		

Figure.1 shown Post operative pain**Figure.2** shown Hospital stay and time of complete healing